

Anterior controllable antedisplacement and fusion as revision surgery for the treatment of OPLL after anterior and posterior decompression: A case report

Article history:

Received: 04-06-2023

Revised: 23-11-2023

Accepted: 25-11-2023

Tianyu Jin^a, Wanru Duan^b, Zan Chen^c

ABSTRACT

Background: In cases of cervical ossification of the posterior longitudinal ligament (OPLL), when initial anterior or posterior decompression fails to yield satisfactory results, the alternative approach is often chosen for revision surgery. Nevertheless, there is a lack of reported information regarding the treatment and prognosis of patients with complex OPLL who have undergone both anterior and posterior decompression but experienced relapse.

Case presentation: A 79-year-old male patient presented with numbness, weakness, and muscle atrophy in the right upper extremity, along with weakness in the right lower extremity. Initial assessment on admission revealed a Japanese Orthopaedic Association (JOA) score of 7. The patient previously underwent anterior cervical discectomy and fusion (ACDF) 25 years ago for spinal stenosis, followed by posterior laminectomy as revision surgery. After experiencing recurrent symptoms following a fall one year ago, the patient underwent a second revision surgery using the anterior controllable antedisplacement and fusion (ACAF) technique which led to symptom improvement, and resulted in a postoperative JOA score of 14 at 3 months of follow-up.

Conclusions: Treatment of OPLL patients with symptom recurrence after traditional anterior and posterior decompression is challenging. ACAF offers a viable solution for managing this complex case.

Keywords: Cervical, Ossification of Posterior Longitudinal Ligament; Anterior Controllable Antedisplacement and Fusion; Revision.

^a Department of Neurosurgery, Xuanwu Hospital, Capital Medical University, Beijing, China.

^b Department of Neurosurgery, Xuanwu Hospital, Capital Medical University, Beijing, China. Spine Center, China International Neuroscience Institute (CHINA-INI), Beijing, China.

^c Department of Neurosurgery, Xuanwu Hospital, Capital Medical University, Beijing, China. Spine Center, China International Neuroscience Institute (CHINA-INI), Beijing, China. Corresponding Author: chenzan66@163.com

BACKGROUND

Cervical OPLL is a common cause of cervical spondylosis, often requiring surgical decompression in patients with progressive symptoms [1]. Both anterior and posterior decompression approaches are utilized for OPLL treatment. In cases with high OPLL predominance and cervical kyphosis, direct anterior decompression can be more effective in achieving neurological improvement compared to indirect posterior decompression [2]. However, multisegmental OPLL and combined dural ossification pose technical challenges and risks to traditional anterior decompression techniques, such as anterior cervical corpectomy and fusion (ACCF) [3]. The ACAF technique offers a viable alternative by avoiding direct stripping of the tightly adherent OPLL and ossified dura, reducing the risk of complications and cerebrospinal fluid leakage [4,5].

CASE PRESENTATION

A 79-year-old man presented with a 25-year history of numbness and weakness on the right side. An MRI of the cervical spine revealed cervical stenosis. The patient initially underwent an ACDF procedure involving the C4-5 and C5-6 intervertebral discs. However, one year after the operation, his symptoms recurred, leading to a subsequent posterior cervical laminectomy and decompression. One year ago, the patient experienced a fall, resulting in muscle atrophy in his right hand and difficulty lifting his right lower limb. He also reported a sensation akin to stepping on cotton. Physical examination revealed a motor deficit in the right limbs,

with muscle strength of 3 out of 5 in the upper limb and 4 out of 5 in the lower limb. Muscle tone was observed to be normal, but superficial sensory abnormalities were noted in the right upper and lower limbs. The JOA score was 7. Further examination indicated increased right knee reflex and positive signs of Babinski's and Hoffman's on the right side. Radiographic evaluations, including X-ray plain radiograph and CT scans, demonstrated the post-ACDF changes, right C3-5 laminar decompression, cervical C4-6 continuous OPLL, C4-5 and C5-6 intervertebral cages collapsed posteriorly, and cervical kyphosis deformity (Fig. 1A, B, C). Furthermore, cervical MRI findings supported the presence of C4-6 cervical spinal stenosis (Fig. 1D).

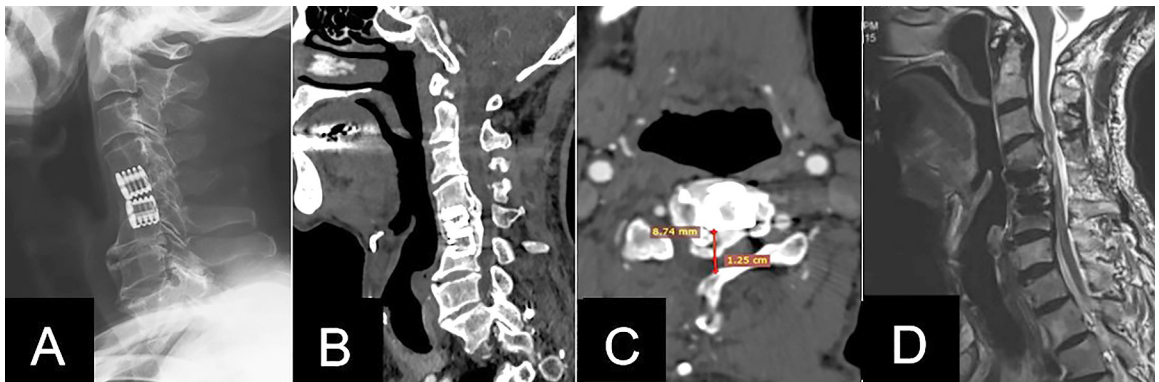

Figure 1. Preoperative Head and Neck Imaging: X-ray, CT, and MRI Images of the Patient.

X-ray reveals postoperative changes following ACDF (A). Sagittal CT reveals right C3-5 laminar decompression, cervical C4-6 continuous OPLL, C4-5 and C5-6 intervertebral cages collapsed posteriorly, and cervical kyphosis deformity. The preoperative axial CT image demonstrates approximately 70% segmental ossification of the posterior longitudinal ligament at the C5 level (C). MRI image illustrates cervical spinal canal stenosis at C4-6 (D).

The ACAF technique was utilized under general anesthesia to lift the C4-6 vertebral body, aiming to alleviate the compression of the spinal cord. The patient was positioned in a supine position. A diagonal incision was made along the left anterior border of the sternocleidomastoid muscle, using the Smith-Robinson approach to expose the anterior aspect of the vertebral bodies. The longus colli muscles were separated bilaterally, and the C3-4 and C6-7 intervertebral discs were removed. Fusion cages were inserted, and resection was performed on the anterior vertebral bodies of the C4-6. Left-sided troughs lateral to the OPLL were drilled at C4, C5

and C6 anteriorly using a high-speed burr. The anterior vertebral bodies of C4 to C6 were shaved down using a high speed to allow room for antedisplacement. An anterior cervical plate was placed from C3 to C7. Distraction screws were placed at C4 and C6. Lateral to the OPLL were drilled at C4, C5 and C6 anteriorly using a high-speed burr. The vertebral bodies were pulled anteriorly. An intraoperative O-arm scan confirmed the satisfactory position of the internal fixation system.[6]

The patient reported an immediate improvement in symptoms after surgery. The muscle strength of the right upper limb recovered from grade 3 to grade 4, and the numbness was alleviated. And symptoms continued to alleviate within three days post-surgery. Imaging examinations showed improved cervical kyphosis, the forward shift of the vertebrae-OPLL complex, and a significantly wider anteroposterior diameter of the cervical spinal canal compared to preoperative measurements. (Fig. 2). At a 3-month follow-up, the muscle strength of the right limb reached grade 5. JOA score increased

to 14. Postoperative cervical spine CT imaging demonstrated satisfactory antedisplacement of the corresponding segmental vertebral body, proper positioning of the internal fixation system, and

restoration of the cervical spine curvature. A follow-up cervical spine MRI performed two years postoperatively revealed complete relief of the compression on the cervical spinal cord (Fig. 3).

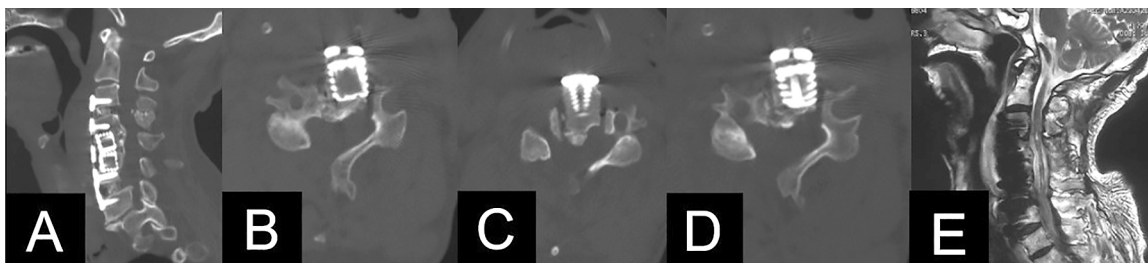


Figure 2. Postoperative Imaging Examination Images 2 Days After ACAF Surgery.

Sagittal CT reveals improved cervical kyphosis, the forward shift of the vertebrae-OPLL complex, and a significantly wider anteroposterior diameter of the cervical spinal canal compared to preoperative

measurements. The stenosis has significantly improved in comparison to the preoperative condition. MRI images also confirm the improvement in spinal canal stenosis compared to preoperative scans.

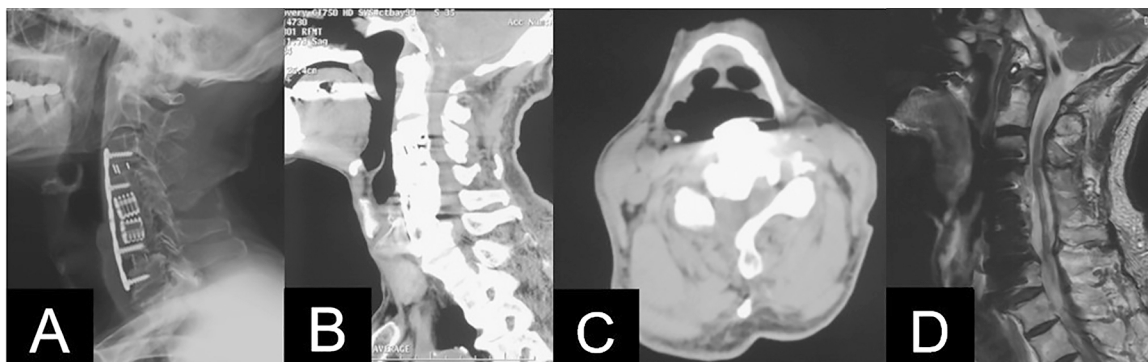


Figure 3. Long-term Follow-up Imaging: X-ray, CT, and MRI Evaluation 2 Years after ACAF.

The X-ray examination indicates satisfactory elevation of the vertebral body at the corresponding segment, proper positioning of the internal fixation system, and restoration of the curvature of the cervical spine (A). Sagittal and axial CT demonstrating the formation of bony fusion (B,C). MRI illustrating complete relief of spinal canal compression (D).

DISCUSSION

The patient had previously undergone both anterior and posterior surgeries to address cervical stenosis caused by OPLL. However, these procedures failed to fully alleviate the compression on the cervical medulla, resulting in a progressive deterioration of the patient’s neurological function. Furthermore, the anterior internal fixation system experienced a severe collapse, leading to the development of

progressive cervical kyphosis, which further exacerbated the compression of the cervical medulla. To effectively treat the patient, it is imperative to relieve the spinal cord compression and correct the cervical spine’s physiological curvature.

Symptomatic spinal canal stenosis, multilevel OPLL, and staged cervical kyphosis with negative K-line are some of the most common indications for ACAF surgery. In patients presenting with a negative K-line associated with large vertebrae-OPLL complex and cervical kyphosis, the treatment plan involving posterior laminar decompression is not appropriate for correcting the kyphosis and relieving the compression on the ventral side of the cervical spinal cord [7,8]. Considering the patient’s CT scan revealing significant OPLL at the posterior edge of the vertebral body and the fact that the patient had previously undergone a two-segment ACDF procedure, the dural ossification (DO) could

be predicted. Performing an ACCF procedure to remove the diseased segment of the vertebral body may lead to difficulties due to the potential risk of a large dural defect. In addition, the reconstruction of three vertebral segments may potentially lead to short-term and long-term complications such as instability and collapse.

The ACAF procedure offers a novel and effective solution for addressing this challenging case. By partially resecting the front edge of the affected segment and performing osteotomies on both sides, the lesion segment can be pulled forward. This approach effectively relieves the compression on the patient's cervical spinal cord and corrects the curvature of the cervical spine. Importantly, it minimizes the risk of dura mater damage and the occurrence of cerebrospinal fluid fistula. Additionally, the ACAF technique reduces the likelihood of internal fixation failure in long-segment cervical anterior column reconstruction [4,8,9].

Considering the patient's symptomatic spinal canal stenosis and progressive OPLL, revision surgery was deemed necessary. The patient exhibited segmental cervical kyphosis, and posterior laminoplasty proved ineffective for anterior decompression. Given the significantly elevated risk of complications with long-segment ACCF surgery in a 79-year-old patient, we opted for the ACAF technique for the revision surgery. Moreover, the utilization of microscope-assisted techniques in performing ACAF surgery is highly recommended. The key advantages of microscope assistance include precise identification and adequate decompression of the hooked facet joints, thorough removal of the bone trough, and the safe management of longitudinally extended ossified lesions using the "nesting" technique [6]. These techniques minimize potential complications associated with the procedure, such as vertebral artery injury, failed anterior translation of vertebral bodies, and adjacent segment disease resulting from multilevel fusion [10].

CONCLUSION

In conclusion, the ACAF technique serves as a viable alternative for revision surgery in cases where posterior decompression for OPLL is not available. It offers an effective solution in complex scenarios after anterior decompression, highlighting its versatility and applicability in managing challenging cases.

Abbreviations

OPLL: Ossification of the posterior longitudinal ligament

JOA: Japanese Orthopedic Association

ACDF: Anterior cervical discectomy with fusion

CT: Computed tomographic

ACAF: Anterior controllable antedisplacement and fusion

ACCF: Anterior cervical corpectomy and fusion

K-line: Kyphosis line

DO: Dural ossification

DECLARATIONS

Ethics approval and consent to participate

Not applicable

Consent for publication

The participant had signed the informed consent for clinical research at Xuanwu Hospital.

Availability of data and materials

All data generated or analyzed during this study are included in this published article.

Competing interests

The authors declare that they have no competing interests.

Funding

The "Young Talents" Program, supported by Beijing Municipal Hospital Administration (No. QML20210801).

Beijing Natural Science Foundation Grant (No. L212039).

Authors' contributions

Formal Analysis: Zan Chen

Methodology: Zan Chen

Project Administration: Wanru Duan, Zan Chen

Writing – Original Draft: Tianyu Jin, Wanru Duan, Zan Chen

Writing – Review & Editing: Tianyu Jin, Wanru Duan, Zan Chen

Acknowledgments

This manuscript was previously submitted to the Clinics of Surgery but was withdrawn before acceptance. However, the journal demanded a substantial withdrawal fee, which was disregarded. This is the only explanation

The preprint version of this manuscript has already been published at <https://www.biorxiv.org>.

REFERENCES

- [1] YOUSSEF JA, HEINER AD, MONTGOMERY JR, TENDER GC, LORIO MP, MORREALE JM, PHILLIPS FM. (2019). Outcomes of posterior cervical fusion and decompression: a systematic review and meta-analysis. *Spine Journal*, 19(10), 1714-1729. DOI: 10.1016/j.spinee.2019.04.019
- [2] LE HV, WICK JB, VAN BW, KLINEBERG EO. Ossification of the Posterior Longitudinal Ligament: Pathophysiology, Diagnosis, and Management. *J Am Acad Orthop Surg*. 2022 Sep 1;30(17): 820-830. doi: 10.5435/JAAOS-D-22-00049.
- [3] ZILELI M, AKINTÜRK N. (2021). Commentary: Microsurgical Anterior Controllable Antedisplacement Fusion to Treat Cervical Ossified Posterior Longitudinal Ligament: 2-Dimensional Operative Video. *Operative Neurosurgery (Hagerstown)*, 20(3), E222-E224. DOI: 10.1093/ons/opaa439
- [4] SUN J, SHI J, XU X, YANG Y, WANG Y, KONG Q, YANG H, GUO Y, HAN D, JIANG J, SHI G, YUAN W, JIA L. (2018). Anterior controllable antedisplacement and fusion surgery for the treatment of multilevel severe ossification of the posterior longitudinal ligament with myelopathy: preliminary clinical results of a novel technique. *European Spine Journal*, 27(6), 1469-1478. DOI: 10.1007/s00586-017-5437-4
- [5] CHEN Y, SUN J, YUAN X, GUO Y, YANG H, CHEN D, SHI J. (2020). Comparison of Anterior Controllable Antedisplacement and Fusion With Posterior Laminoplasty in the Treatment of Multilevel Cervical Ossification of the Posterior Longitudinal Ligament: A Prospective, Randomized, and Control Study With at Least 1-Year Follow Up. *Spine*, 45(16), 1091-1101. DOI: 10.1097/BRS.00000000000003462
- [6] DUAN W, CHOU D, JIAN F, CHEN Z. Microsurgical Anterior Controllable Antedisplacement Fusion to Treat Cervical Ossified Posterior Longitudinal Ligament: 2-Dimensional Operative Video. *Oper Neurosurg (Hagerstown)*. 2021 Feb 16;20(3): E221. DOI: 10.1093/ons/opaa376.
- [7] LEE, D.-H., PARK, S., & HONG, C. G. (2020). A novel anterior decompression technique for kyphosis line (K-line) ossification of posterior longitudinal ligament (OPLL): vertebral body sliding osteotomy. *Journal of Spine Surgery*, 6(1), 196-204. DOI: 10.21037/jss.2019.12.05.
- [8] SUN, J., SHI, J., XU, X., YANG, Y., WANG, Y., ET AL. (2018). Anterior controllable antedisplacement and fusion surgery for the treatment of multilevel severe ossification of the posterior longitudinal ligament with myelopathy: preliminary clinical results of a novel technique. *European Spine Journal*, 27(6), 1469-1478. DOI: 10.1007/s00586-017-5437-4.
- [9] WANG, H., SUN, J., TAN Y., LI P., XU M., ET AL. (2019). Anterior Controllable Antedisplacement and Fusion as Revision Surgery After Posterior Decompression Surgery in Patients with Ossification of the Posterior Longitudinal Ligament. *World Neurosurgery*, Mar:123: e310-e317. DOI: 10.1007/s00586-017-5437-4.
- [10] YU, C., SUN, J., YUAN, X., GUO, Y., YANG, H., ET AL. (2020). Comparison of anterior controllable antedisplacement and fusion with posterior laminoplasty in the treatment of multilevel cervical ossification of the posterior longitudinal ligament: a prospective, randomized, and control study with at least 1-year follow up. *Spine*, 45(16):1091-1101. DOI: 10.1007/s00586-017-5437-4.





Publisher's note: Eurasia Academic Publishing Group (EAPG) remains neutral with regard to jurisdictional claims in published maps and institutional affiliations.

Open Access. This article is licensed under a Creative Commons Attribution-NonCommercial 4.0 International (CC BY-NC 4.0) licence, which permits copy and redistribute the material in any medium or format for any purpose, even commercially. The licensor cannot revoke these freedoms as long as you follow the licence terms. Under the following terms you must give appropriate credit, provide a link to the license, and indicate if changes were made. You may do so in any reasonable manner, but not in any way that suggests the licensor endorsed you or your use. If you remix, transform, or build upon the material, you may not distribute the modified material. To view a copy of this license, visit <https://creativecommons.org/licenses/by-nc/4.0/>.